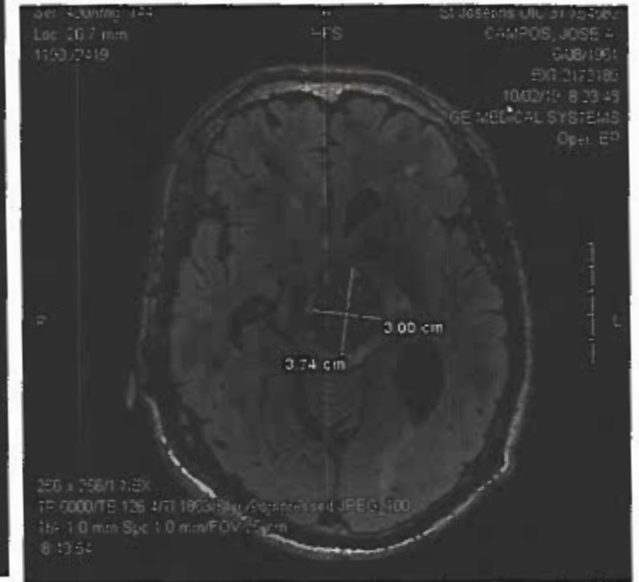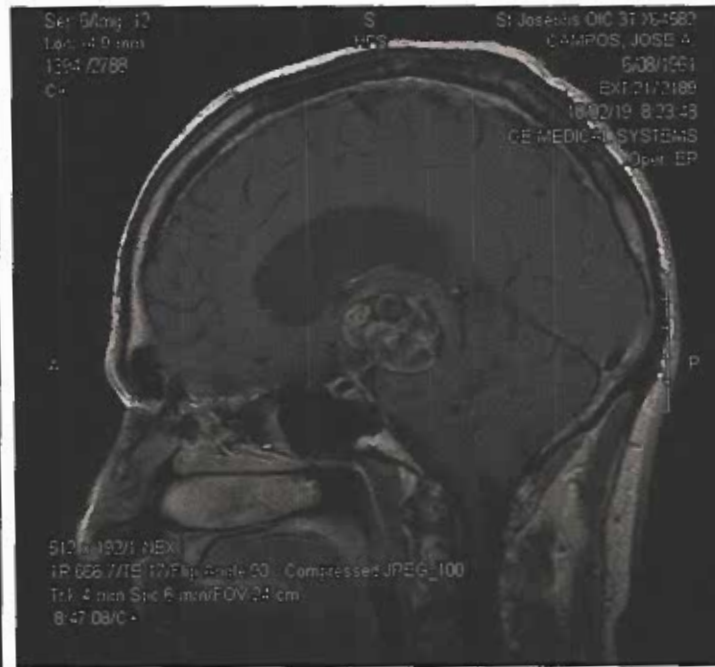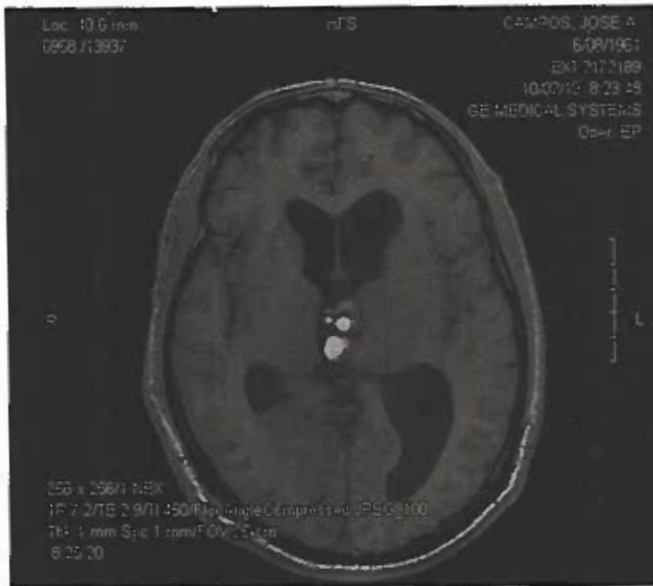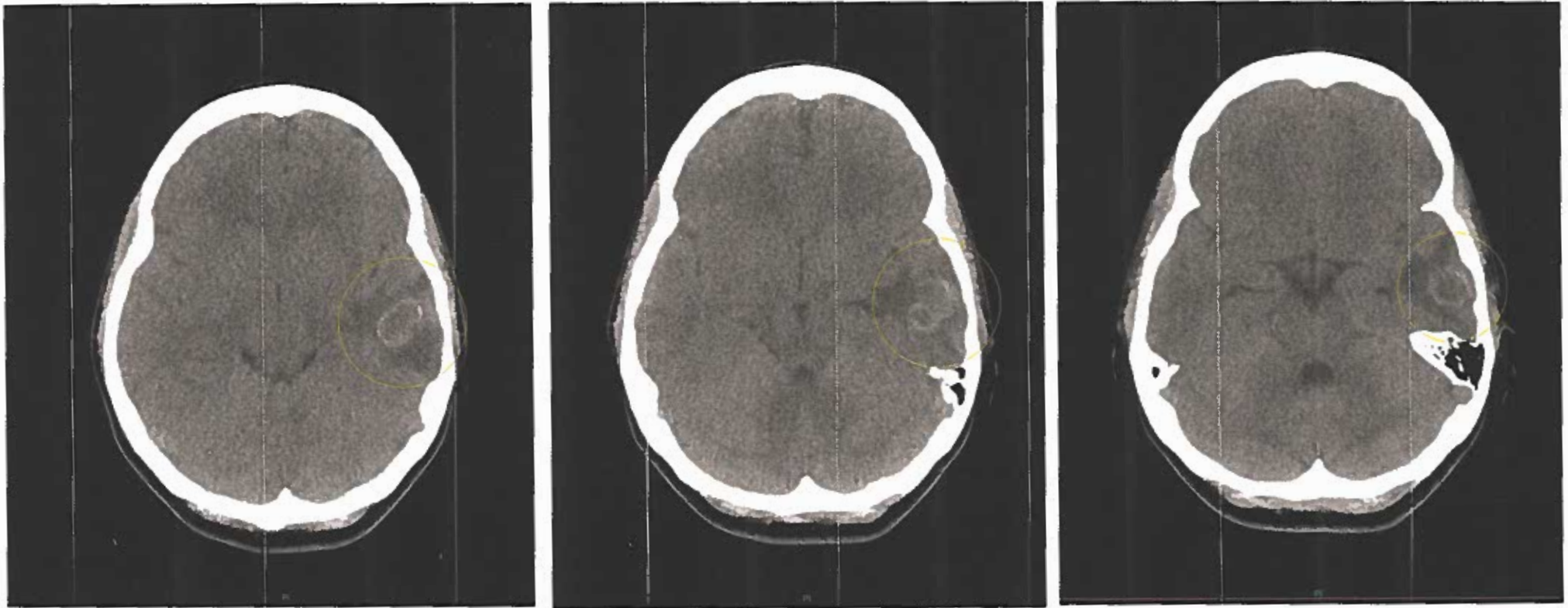
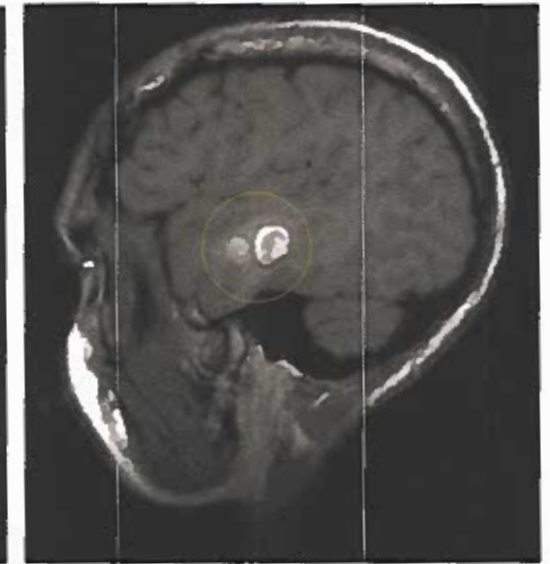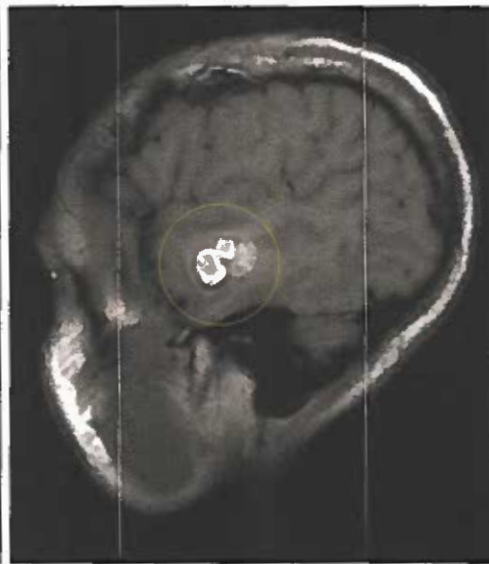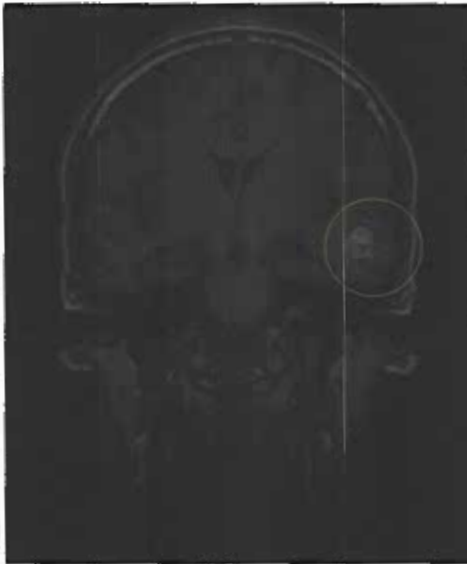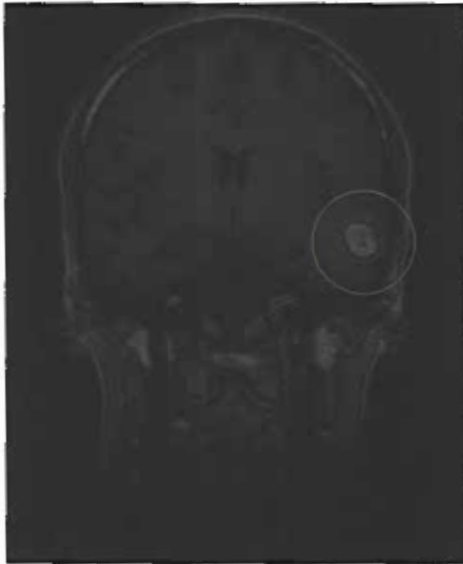
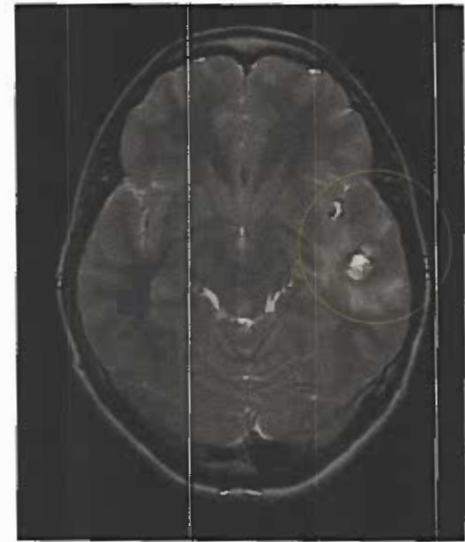
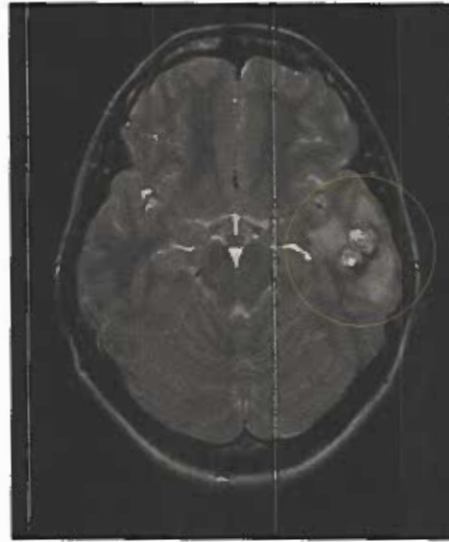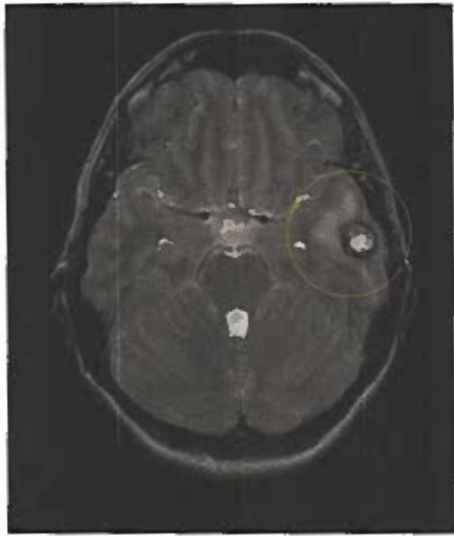


Jose A. Campos  
MRI w/wo contrast  
10/02/2019  
Intra-thalamic Cavernous Malformation, 3.00 cm x 3.74  
cm x 3.74 cm

# NM LHHS Committee 11/28/22



A Campos, unknown mass  
16 Slice CT wo contrast 08/22/2013



MRI w/wo contrast  
8/23/2013 - GCH  
Cavernous  
Malformation